17

Ultrasound for Gastric Antrum Diameter

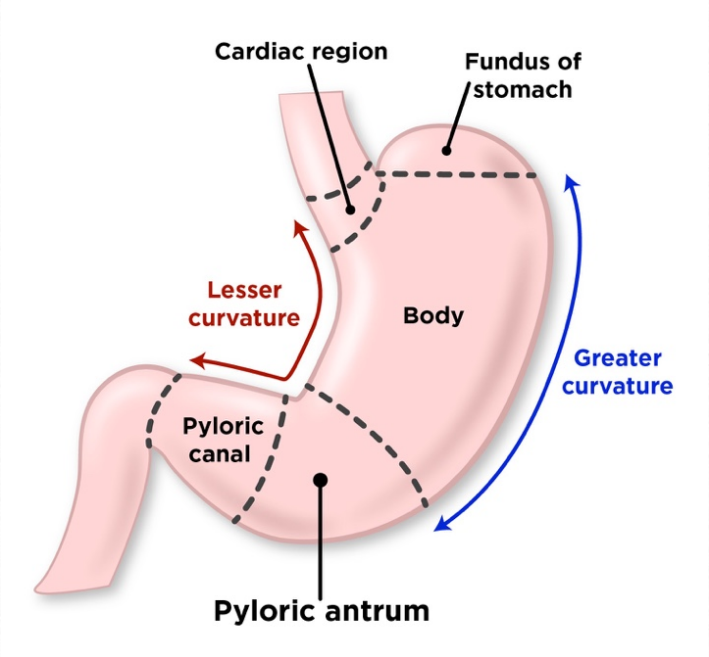

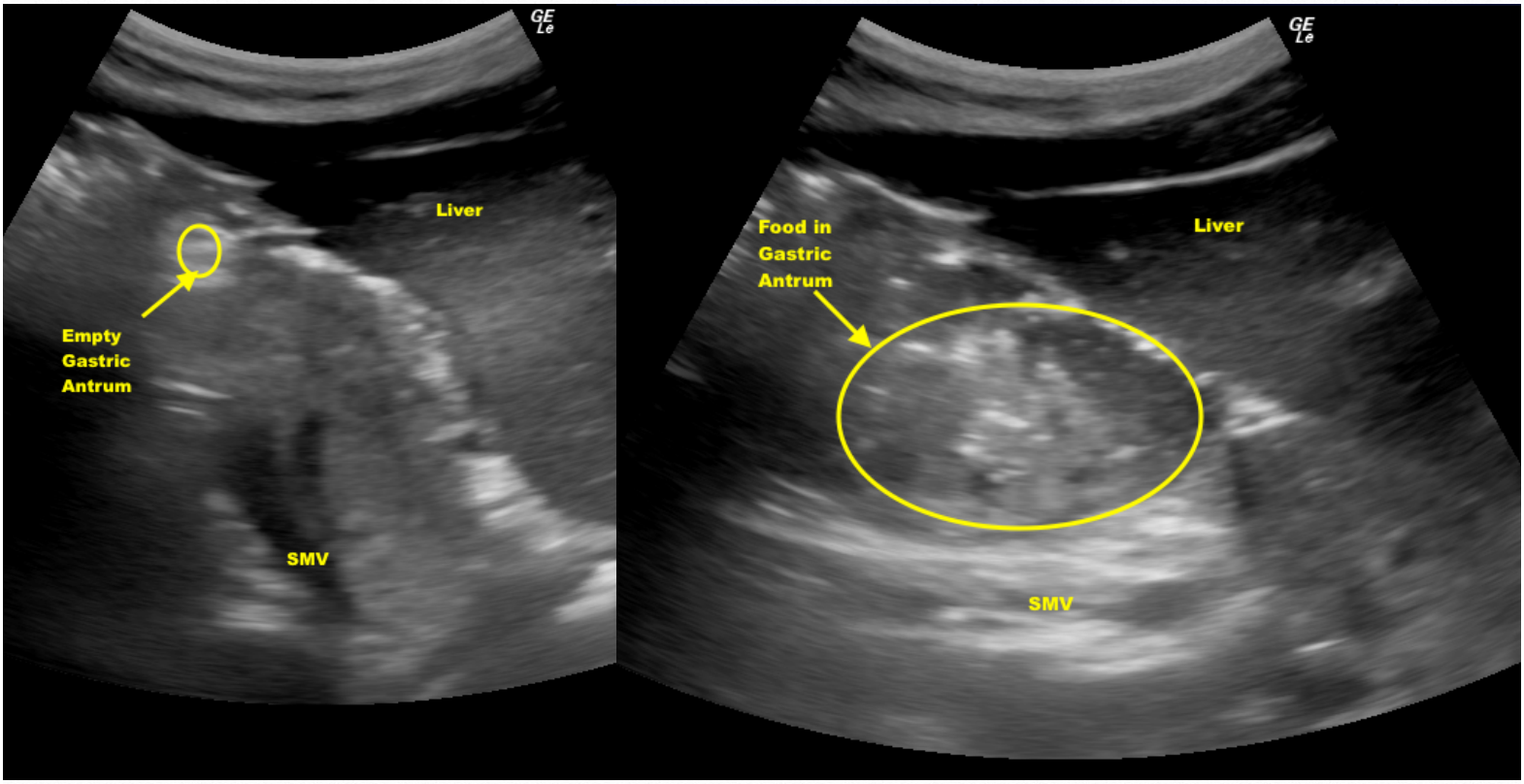

V. Miscellaneous topics – Ultrasound of Gastric Antrum Area

Ultrasound of Gastric Antrum Area: Aspiration of gastric contents can be a serious perioperative complication, associated with significant morbidity and mortality**.**

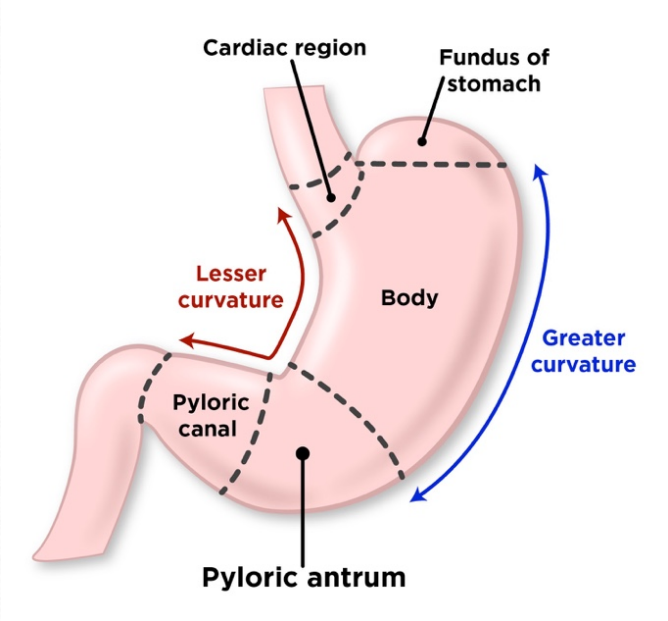

In particular, aspiration of solid particulate matter, large volumes (>0.8ml/kg or 50ml), or fluid with low PH (< 2.5) carries high morbidity. Mortality after aspiration pneumonia can be as high as 5% and it accounts for up to 9% of all anesthesia-related deaths. In addition, it occurs quite frequently in certain populations. For example, it is believed that 38% of all trauma patients have aspirated. Also, several clinical studies have shown that healthy fasting patients frequently have residual gastric volumes larger than previously thought, up to 1.6 mL/kg (well above the volume needed to cause significant complications). In addition, there is some debate that fasting guidelines are not applicable in the urgent or emergent surgical patient, and certain physiologic states (e.g. pregnancy) and medical conditions (e.g. diabetes, trauma, renal, or liver dysfunction) may result in delayed gastric emptying and significant residual gastric volume despite recommended fasting times. Finally, the utility of cricoid pressure has also been debated. This is because studies have shown that **in 50% of the population the esophagus is not behind the trachea,** but rather lateral (90% of the time to the left), therefore making cricoid pressure ineffective for these patients.

Because of significant complications that can occur from aspiration as well as the fact not all of the patients we take care of have fasted, there are many issues that limit the utility of the fasting guidelines. A tool to quickly determine the patient's gastric volume would be extremely useful for anesthesiologists. Fortunately, point of care (POC) ultrasound provides such a modality via the assessment of *gastric antrum area*. Several studies have proven that gastric antrum area, measured by POC US, can easily detect patients with the critical volume of 0.8 ml/kg. For our purposes we will use POC to measure the gastric antrum only and not other areas of the stomach. This is because the gastric antrum is the easiest to ultrasound, and the gastric antrum expands from a baseline empty state as fluid enters the stomach with gastric volume in a close-to-linear manner up to 300 ml. Volumes in excess of 300 ml result in only modest further increases in antral size, with excess volumes being accommodated by more proximal areas of the stomach.

Ultrasound Probe & Position: One should use the **Curved Linear Probe ONLY.** This is because it provides the right combination of frequency, footprint, and depth of penetration. The patient should be slightly head up (25 - 45 degrees) and positioned in slight right lateral decubitus position, which makes measurements more sensitive. The gastric antrum is imaged in a parasagittal plane (indicator somewhere between 11 and 1 o'clock position) in the epigastric area using the left lobe of the liver, the inferior vena cava, and the superior mesenteric vein as internal landmarks. The two vessels are usually visualized slightly to the right of the abdominal midline. Once these vessels are identified, the transducer should be rotated slightly clockwise or counterclockwise to best obtain a true cross-sectional view of the antrum **(the SMALLEST possible cross-sectional view).** The **antero-posterior** and **craniocaudal diameters** are measured in this view.

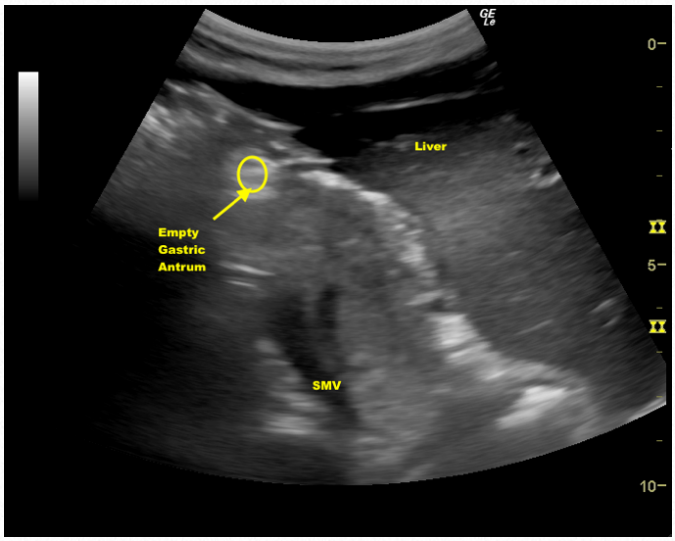

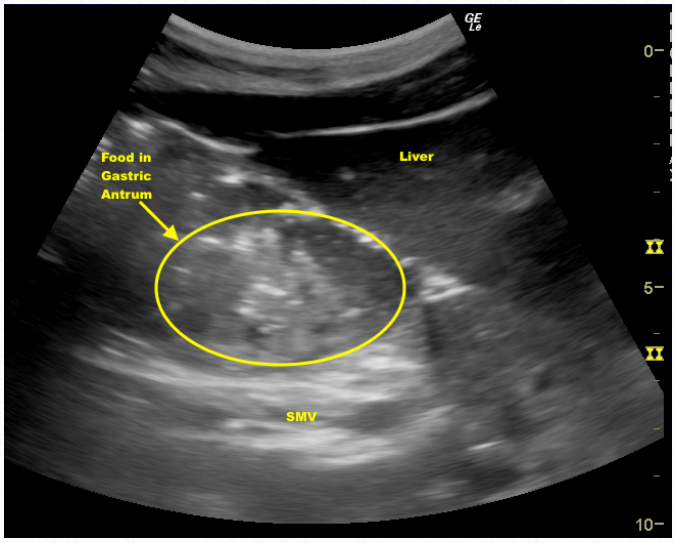

Measurements & Abnormal Image Appearance

The gastric antrum area is calculated by first obtaining the **SMALLEST possible cross-sectional view).** The **antero-posterior** and **craniocaudal diameters** are measured as shown in the pic below. One uses the diameter measurements to calculate the cross sectional area (CSA) using the following equation:

CSA=(AP X CC x π)/4

A **CSA of 4 cm^2 equals an empty stomach. A CSA of 10 cm^2** corresponds to a gastric volume of between **100 and 240 ml.** A **CSA > 10 cm^2** equals a volume over **300ml.**

Clear fluids appears hypoechoic (see pic above) and particulate material (food) appears as a "frosted-glass appearance" (see pic to the right). This frosted-glass appearance is likely related to air mixed with solid food during the swallowing process. Also, remember that placement of the patient in right lateral decubitus position makes measurements more sensitive

Example measurements for cross sectional area calculation.

Calculation for Volume.

Volume (mL) = 1199.99 + 483.09*log (CSA supine) - 5.84*age - 9.94*height

Volume (mL) = -372.54 + 282.49*log (CSA lateral) - 1.68*weight